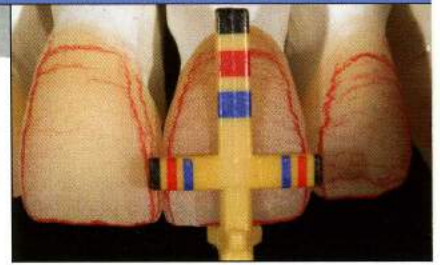


CLINICAL APPLICATION OF INNOVATIVE MEASUREMENT GAUGES FOR PREDICTABLE CORRECTION OF TOOTH SIZE/PROPORTION AND GINGIVAL ARCHITECTURE DISCREPANCIES



Stephen J. Chu, DMD, MSD, CDT¹
Paul D. Fletcher, DDS²
Adam J. Mieleszko, CDT³

Dental professionals have long been guided by mathematical principles when interpreting esthetic proportions for their patients, whether it involves tooth-to-tooth smile arrangement or creating proper tooth dimensions.¹⁻⁴ While many acknowledge that such principles are merely initiation points for a given smile design or reconstructive procedure, their very existence appears to indicate practitioners' desire for some predictable, objective, and reproducible means of achieving success in esthetic dentistry.

The belief that the Golden Proportion unequivocally defines the standard by which anterior teeth

should be arranged has been perpetuated by authors such as Lombardi, Levin, and Rufenacht, who wrote intellectually stimulating articles and books, respectively, on esthetics and design.^{1,2,5} These concepts have been developed into usable tools such as the Golden Proportion Ruler (Bayview Dental Lab, Chesapeake, VA, USA) and the Golden Proportion waxing templates (Panadent, Grand Terrace, CA, USA). The clinical reality, however, is that intra-arch tooth arrangement guidelines such as the Golden Proportion are only applicable to a minority segment of the patient population and pose some difficulty in their implementation.⁶⁻⁸

In the 1990s, Preston demonstrated that the Golden Proportion existed in the relationship between the maxillary central and lateral incisors in only 17% of patients studied.⁹ Studies by Ward also suggest that the Golden Proportion should not be considered the intra-arch tooth proportion standard.¹⁰ Since 2001, Ward has done a significant amount of "perception-based" research comparing dental professionals' and patients' preferred choice of smile design based on the results of smiles created using the Recurring Esthetic Dental (RED) Proportion, the

¹Clinical Associate Professor and Director, Advanced CDE Program in Esthetic Dentistry, Department of Periodontology and Implant Dentistry, New York University College of Dentistry; private practice, New York, New York, USA.

²Associate Clinical Professor, Department of Periodontology and Implant Dentistry, New York University College of Dentistry, New York, New York, USA.

³New York, New York, USA.

Correspondence to: Dr Stephen J. Chu, NYU College of Dentistry, 150 East 58th Street, Suite 3200, New York, NY 10155, USA. E-mail: schudmd@aol.com

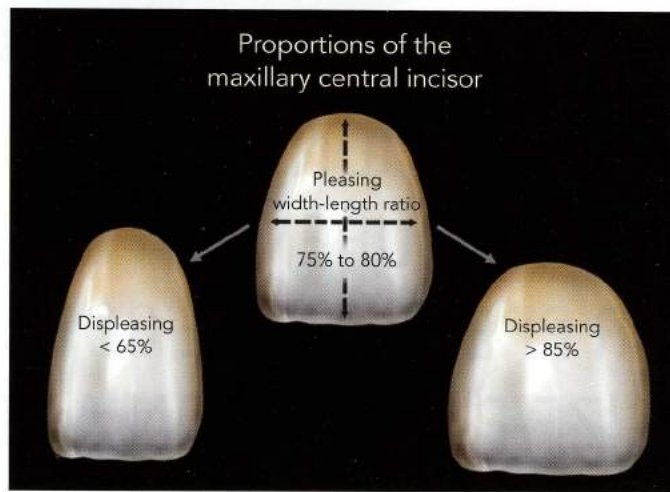


Fig 1 The most pleasing width-length ratio falls between 75% and 80%. (Courtesy of Dr Gerard Chiche.)

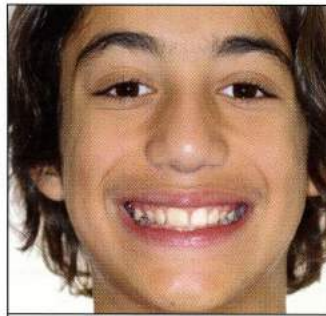Golden Proportion, or naturally occurring tooth-to-tooth width proportion relationships previously reported in the North American population.^{7,10,11} His findings suggest that universal application of the Golden Proportion should be reconsidered, as it was found to be the least pleasing and least accepted among dentists and patients in the United States.¹⁰

Conversely, tooth size, composed of width and length dimensions, is a critical element in esthetics and can be considered one of the building blocks of the smile. Tooth size is directly related to tooth proportion, which is expressed as tooth width divided by tooth length times 100. An analogy can be made to the edentulous patient, where the first step is selection of the correct mold or tooth size harmonious within the dental arch, prior to tooth arrangement. This task cannot be accomplished successfully if the teeth selected are inadequate horizontally and/or vertically in dimension. The same applies to the dentate patient, in whom the dentition often presents with variations in tooth size that ultimately negatively affect not only tooth proportion but also the gingival architecture. Tooth proportion values above 85% lend to the appearance of excessively short and square teeth, while those below 65%, similar to mandibular anterior teeth, appear too long and rectangular (Fig 1).

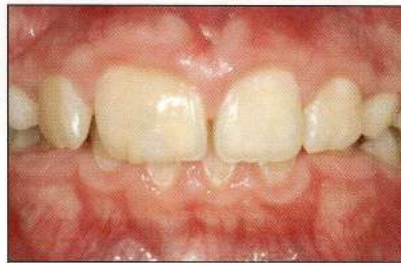SIZE MATTERS

Tooth proportion values for anatomic teeth vary from 73% to 78%, while clinical crowns are slightly higher, ranging from 76% to 86%.¹²⁻¹³ Combining these studies on tooth proportion values gives an average of approximately 80%. In addition, mean values for tooth dimensions cannot be used routinely or predictably, since they apply only about a third of the time. Tooth size variation is the rule (~66%), not the exception; however, tooth proportion remains constant. Nevertheless, 80% of the population will reside at ± 0.5 mm of these mean values. There is also a correlation between the width of the central incisor, lateral incisor, and canine teeth. Invariably, the widths of the lateral incisor and canine teeth are predicated on the central incisor being 2 mm and 1 mm less in width, respectively, for average to large teeth. For smaller teeth, the relationship is constant but the lateral incisor is 1.5 mm less in width, with the canine remaining 1 mm less than the central.¹⁴

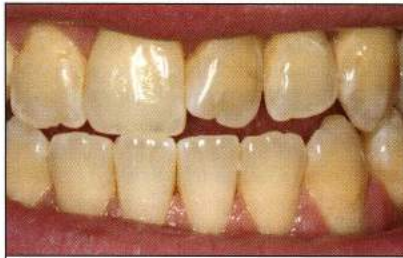Tooth shape is also a critical factor in the perception of tooth width, especially with multiple-tooth restorations; however, changes in form and contour are limited when addressing tooth length discrepancies.



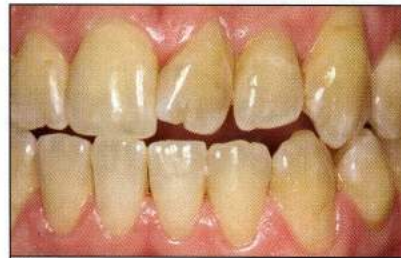2a



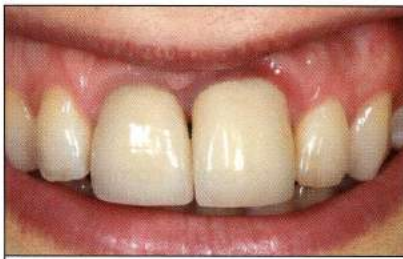2b



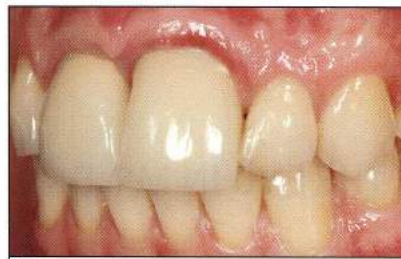3a



3b



4a



4b

Figs 2a and 2b A malformed dentition is often the result of hereditary predisposition. Note the macrodontia (maxillary right central incisor), which will ultimately affect the patient's esthetic and occlusal outcome.

Figs 3a and 3b Microdontia (maxillary left central incisor) negatively affects the dentofacial appearance of the smile. The tooth's diminutive size impacts the occlusal scheme, which in this case is a Class 3 malocclusion.

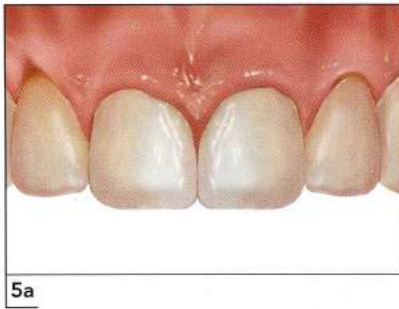Figs 4a and 4b Restorations created without definitive proportion guidelines (ie, those determined by "eyeballing") can result in inadequate esthetic and occlusal outcomes.

FACTORS AFFECTING TOOTH SIZE

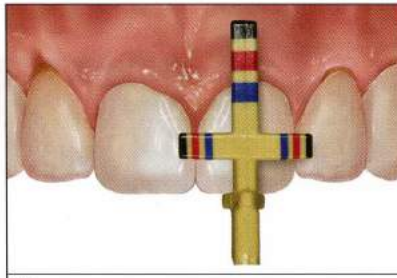
In daily practice, clinicians observe teeth whose sizes are abnormal relative to accepted clinical crown width and height values (Figs 2 and 3). Etiologies that contribute to malformed or incomplete dentitions include hereditary (congenital) conditions such as missing lateral incisors or dentinogenesis imperfecta, and partial odontia with or without transposition of teeth. There are also certain disease states that can lead to compromised tooth structure. These include gastroesophageal reflux disease, which erodes incisal edges, resulting in exces-

sive gingival display as well as compensatory eruption of opposing dentition; bruxism, which causes short teeth due to incisal attrition; and aging, which causes long teeth due to gingival recession.

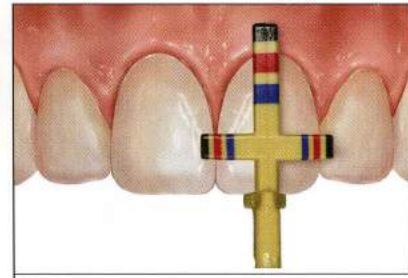
No matter what the cause of tooth-size disparities, when it comes time to restore these teeth, the application of nonstandard proportions, ie, "eyeballing," can yield teeth that are unnatural in size and fail to achieve the esthetic expectations of either dental patient or professional (Figs 4a and 4b). A more definitive, less subjective approach to obtaining ideal restoration parameters is required to obtain clinical success in the final treatment outcome.



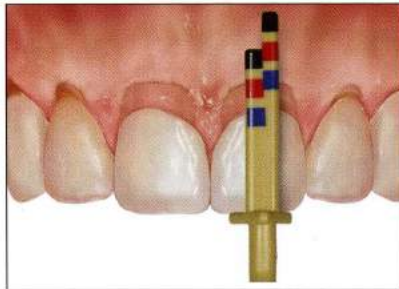5a



5b



5c



6

Figs 5a to 5c Accurate determination of ideal tooth length and width ratios is facilitated with the Proportion Gauge (Hu-Friedy, Chicago, IL, USA). The width is indicated in equidistant increments of color, each with a vertical mark in the corresponding color indicating proportional height. Thus, a central incisor with a "red" width of 8.5 mm will be in proper proportion if its height is also in the "red" zone (ie, 11 mm).

Fig 6 The Crown Lengthening Gauge (Hu-Friedy) has a biologic periogauge (BLPG) tip designed to simultaneously measure the midfacial length of the biologic crown (ie, bone crest to the incisal edge) during surgical crown-lengthening procedures.

BEGIN WITH THE END IN MIND

Whether an esthetic restorative case involves a few anterior teeth or encompasses full-mouth reconstruction, the clinician should be familiar with discrepancies in tooth size at the initial diagnosis and treatment-planning stages. To eliminate some of the subjectivity associated with esthetic treatment planning and restorative care, new clinical tools have been developed to accurately and easily obtain initial tooth size (length and width), and also assist with determining new and proper tooth proportions of each individual restoration.¹³

Through the use of such instrumentation, the clinician is able to apply esthetic and anatomic tooth proportions directly to a patient chairside or indirectly in the dental laboratory during projected treatment planning, as well as objectively determine the intended treatment outcome.¹⁴⁻¹⁵ One of the aforementioned tools features an established rest position at the incisal edge; when a tooth is seated accordingly, the practitioner can accurately evaluate its ideal length and width ratios (Figs 5a and 5b). The width is indicated in equidistant in-

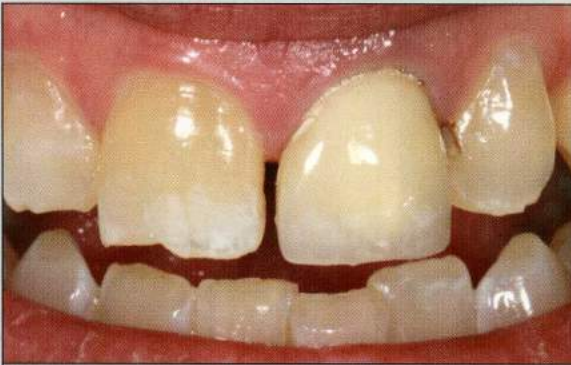crements of color commensurate with measurement values, each with a vertical mark in corresponding color reflective of proportional height (Fig 5c).

Consequently, tooth size and proportion dictate esthetic crown lengthening because teeth often are too short due to incisal-edge changes secondary to parafunction. Should crown lengthening be necessary to achieve an esthetic result, the 1-mm increments marked on the vertical axis of the crown-length tool yield predictable requirements for the increased vertical height and/or interproximal height of bone (Fig 6).

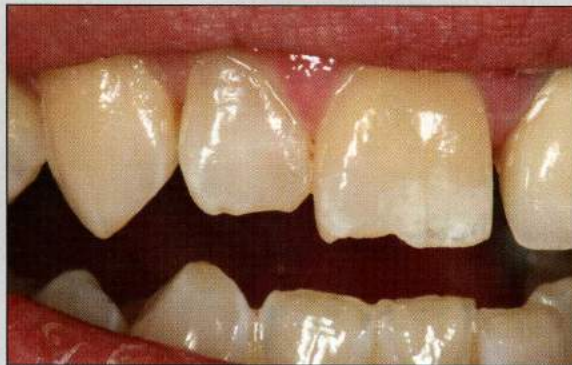CASE PRESENTATION

In the case presentation that follows (Figs 7 to 28), the Aesthetic Gauges (Hu-Friedy, Chicago, IL, USA) are demonstrated in the treatment planning and restoration of a 39-year-old man who presented for esthetic restorative care of fractured anterior teeth and enhancement of the existing dentition. Acci-

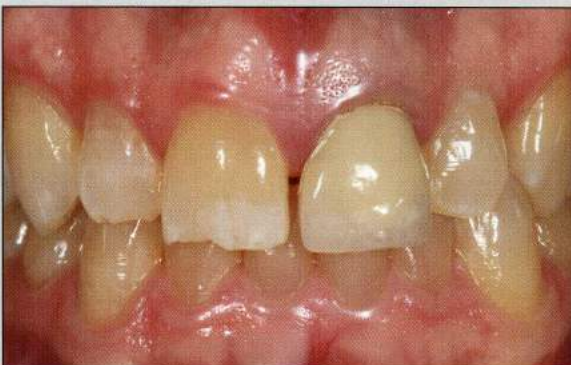CASE PRESENTATION



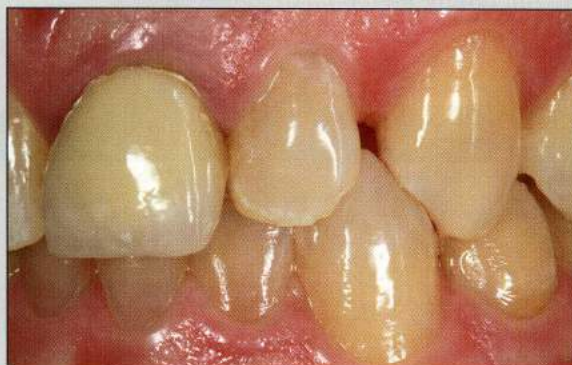7a



7b



8a



8b

Figs 7a and 7b Trauma to the patient's maxillary right central and lateral incisors resulted in fracture of the incisal edges. He was also unhappy with the restorative margin of the maxillary left central full-coverage restoration.

Figs 8a and 8b The patient also presented with excessive overbite relationship of the anterior dentition and tooth-width discrepancies (diastemata) between the central incisors and left lateral incisor and canine.

dental trauma resulted in incisal fracture to the maxillary right central and lateral incisors, and the patient was also unhappy with the left central incisor, a previous full-crown restoration with a gingival margin that had become too short due to the patient's gingival recession. Diastemata between the central incisors and the right lateral incisor and canine were also an esthetic issue requiring corrective measures. The patient presented with a large

tooth size and proportion, which is not uncommon in males. Esthetically and functionally, increasing the incisal length was not an option. Therefore, the treatment plan included crown lengthening on all four maxillary incisors to achieve the proper tooth length relative to the corrected tooth width of the central incisors, which would effectively eliminate the diastemata as well.

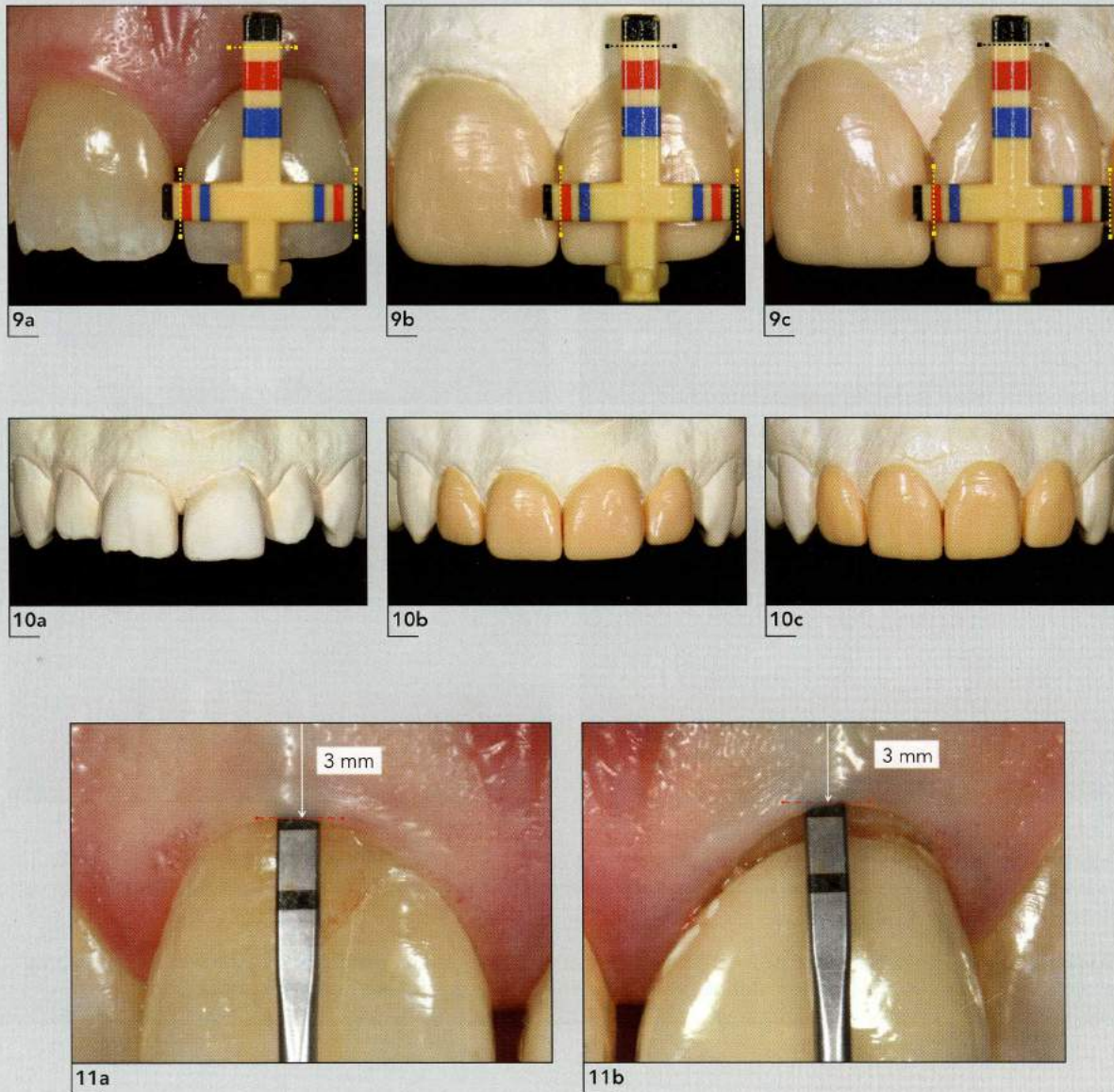


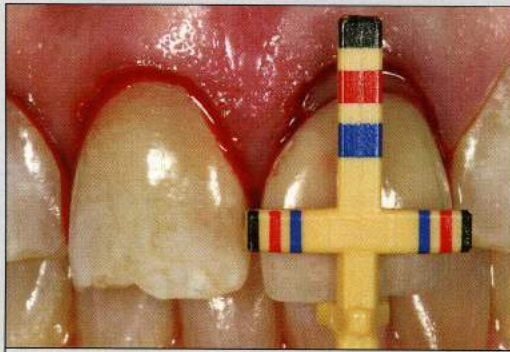
Fig 9a The T-bar tip of the Proportion Gauge indicates the tooth length is not in correct proportion to the width. With an increase in tooth width one colored band unit beyond the outer red borders on the horizontal arm (dotted lines), the proportionally (78%) correct tooth length is half the distance on the vertical yellow band.

Fig 9b Waxup with correction of the width discrepancy only.

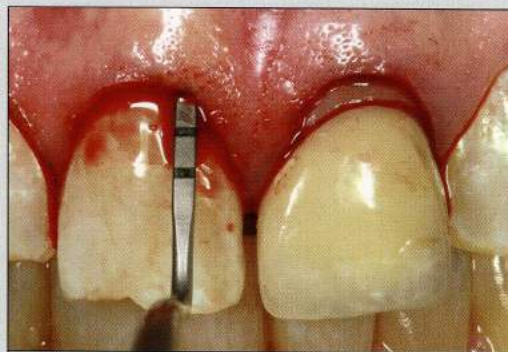
Fig 9c Waxup with correction of the length proportionally guided by the gauge.

Figs 10a to 10c Preoperative stone cast, width correction, and proportional length correction, respectively, show the esthetic outcome of the waxup. Gingival levels and zenith positions will be corrected with the periodontal crown lengthening procedure.

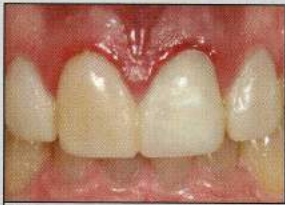Figs 11a and 11b Designed to pierce the supracrestal gingival fibers, a Sounding Gauge is used to determine the level of the bone crest (midfacial osseous crest) prior to flap reflection. The average midfacial den-tingival complex (3 mm) is noted. The curved tip of the Sounding Gauge is 1 mm wide and designed to fol- low the tooth and cements/enamel junction anatomic contours.



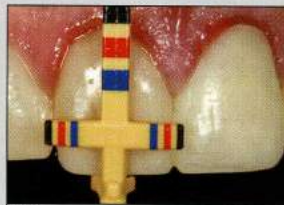
12a



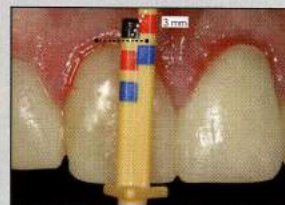12b



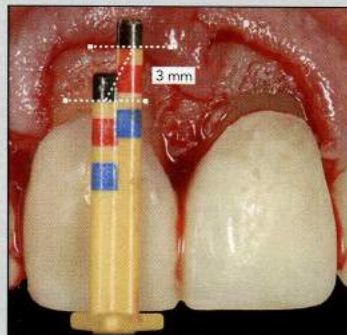
13a



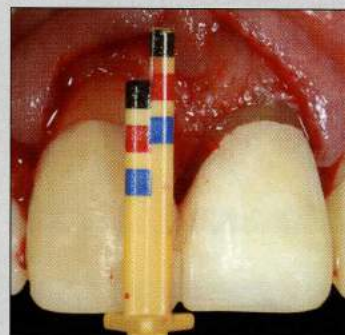
13b



13c



14a



14b

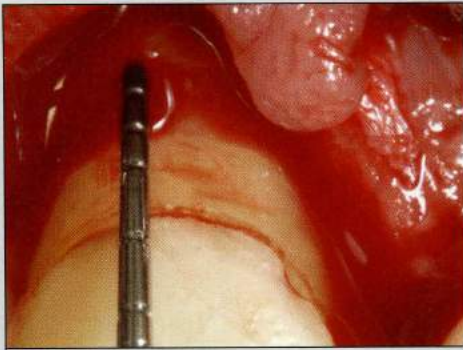
Figs 12a and 12b T-bar tip of the Proportion Gauge is used to assess the correct length of the tooth relative to the new width, and intentional biologic width violation is performed via gingivectomy. After gingivectomy, the Sounding Gauge is placed to assess the bone crest location, which is now about 1 mm (inadequate for biologic and esthetic health).

Fig 13a Provisional restorations are inserted, noting the adverse tissue reaction involving the central incisors following intentional biologic width violation through gingivectomy.

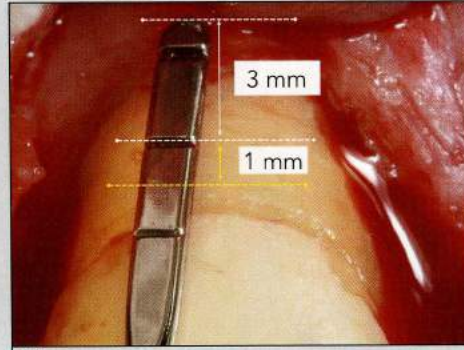
Fig 13b T-bar is used to verify the accurate proportions of the width and length.

Fig 13c BLPG tip is used to measure the midfacial length of the provisional and biologic crown simultaneously at +3 mm.

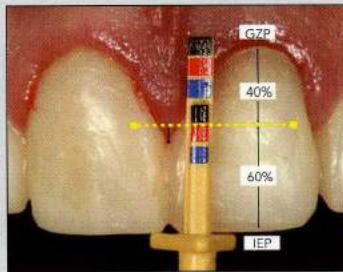
Figs 14a and 14b BLGP tip of the Crown Lengthening Gauge is used for precise visual verification that the proper amount and shape of osseous resection is performed. The corresponding larger measurement was used consistent with the tooth size and proportion analysis, which dictates crown lengthening.



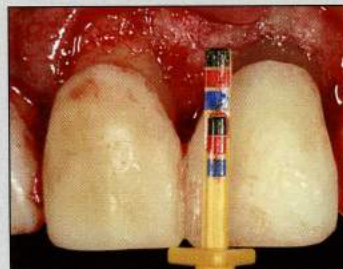15a



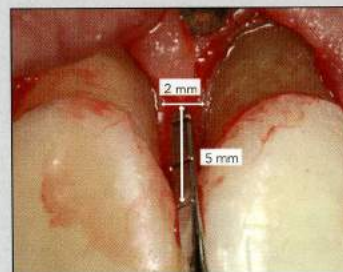
15b



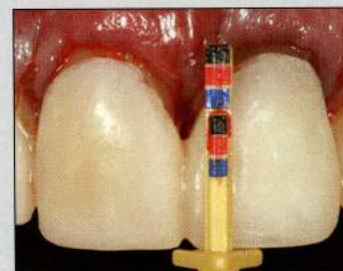
16a



16b



16c



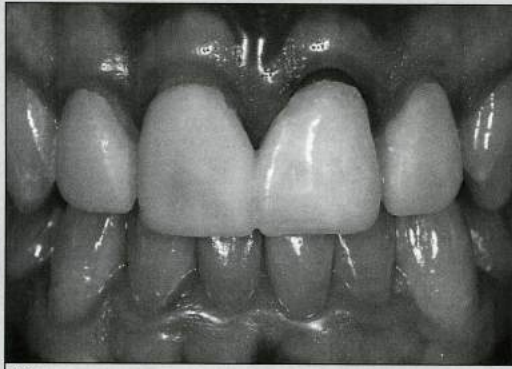16d

Figs 15a and 15b Straight periodontal probe (a) is less accurate in measuring the curvature of the exposed root surface after osseous recontouring compared to the curved Sounding Gauge (b). The Sounding Gauge found 4 mm (vs 3 mm) midfacial sulcus, providing an additional 1-mm sulcus depth to manage the restorative margin location subgingivally.

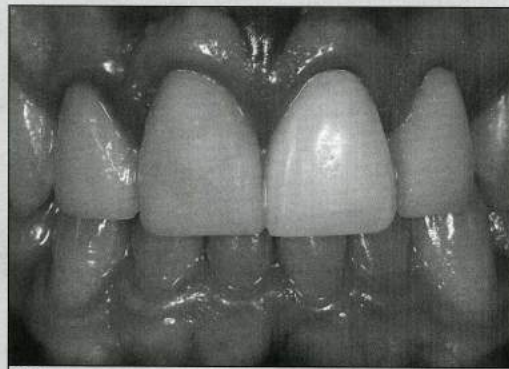Fig 16a Papilla tip of the Crown Lengthening Gauge is used to assess the proper papilla location (dotted line) from the gingival zenith or incisal edge position (40% and 60% incisogingival tooth length, respectively).^{16,17}

Figs 16b and 16c Once the flap is reflected, the surgeon must be able to visualize the clinical soft tissue position of the papilla as well as the interdental bone crest position using the 3- to 5-mm rule.¹⁸

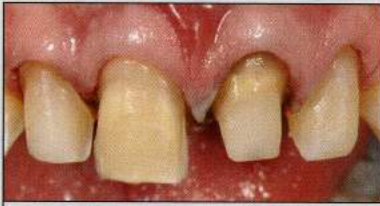Fig 16d Final interdental papilla flap is sutured and its position verified postsurgically using the papilla tip of the Crown Lengthening Gauge.



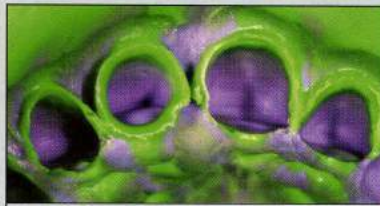
17a



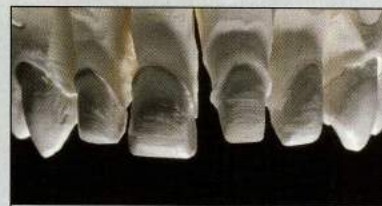17b



18a



18b



18c

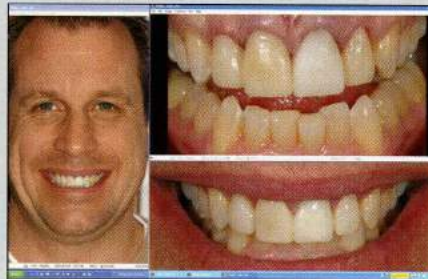Figs 17a and 17b After adequate soft tissue healing (3 months), the provisional restorations were replaced. The correction of the proper tooth size and gingival architecture is now evident.

Fig 18a Once the gingival tissues had healed, the teeth were prepared in a conservative manner for ceramic veneers (right central and right and left lateral incisors) and no-prep veneer (left canine, mesiofacial).

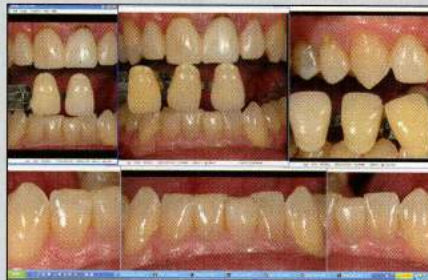Fig 18b Impressions were made.

Fig 18c Stone and refractory casts were fabricated in the lab for restoration construction.

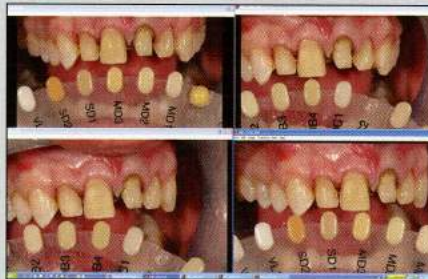Figs 19a to 19c To ensure proper shade matching and communication to the laboratory technician, numerous photographs of both anterior arches were taken and assessed, including full-face, close-up of natural and protracted preoperative smile and teeth, as well as the "stump" preparation shade.



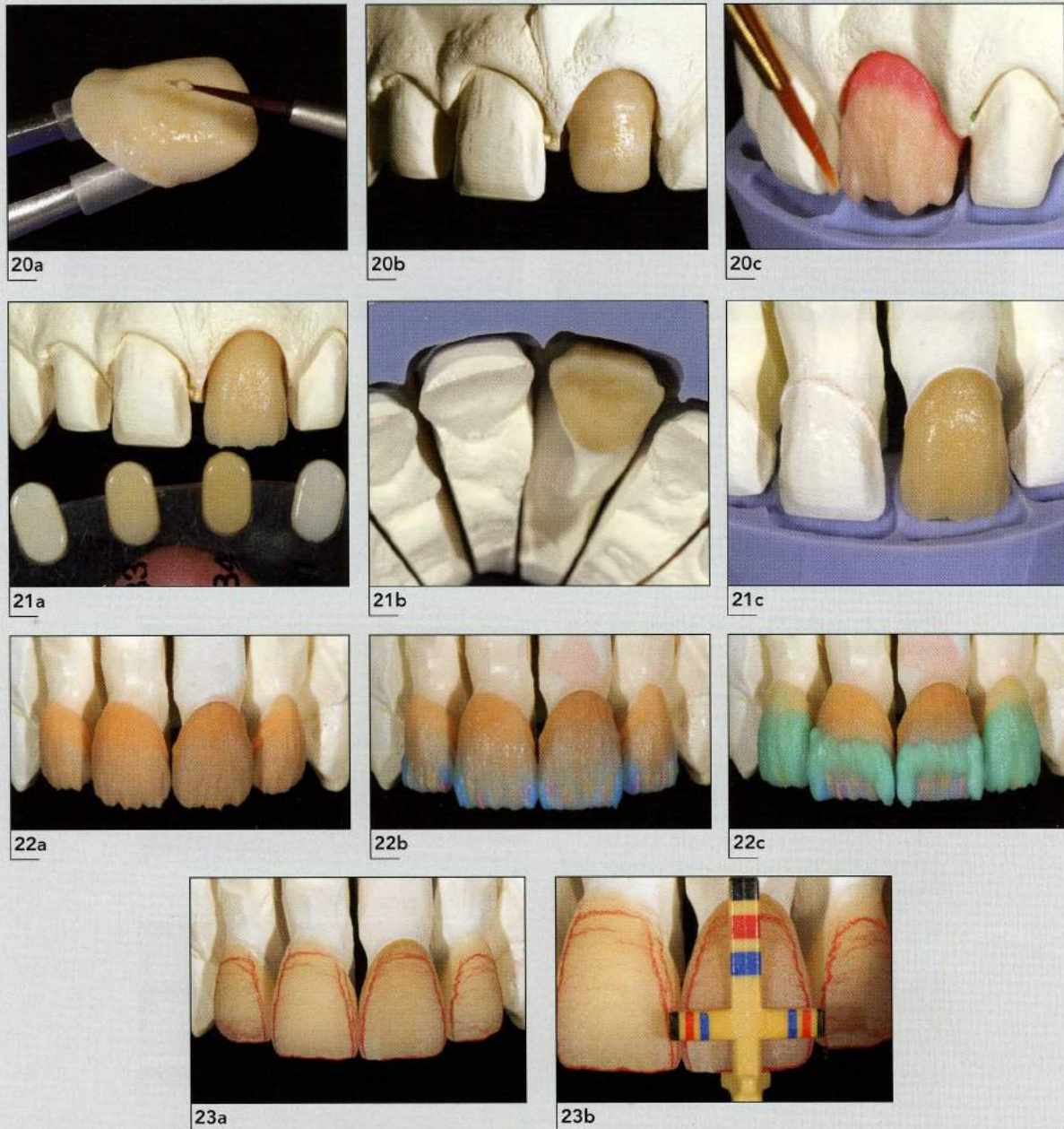
19a



19b



19c



Figs 20a to 20c Full-crown restoration primary “base” shade is colorized to the “stump” shade of the veneered natural teeth. In addition, the shape of the base shade ceramic buildup mimics that of the veneer preparations.

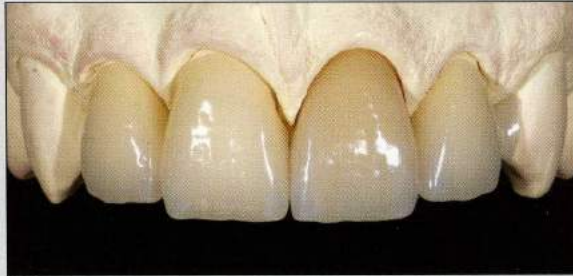Fig 21a Proper “base-stump” shade was confirmed.

Figs 21b and 21c Silicone putty matrix was used to assess the proper facial, proximal, and incisal fabrication of the full crown “stump” relative to the veneer preparations. Subsequent veneering ceramic should be equal for all preparations.

Figs 22a to 22c Further shade matching and characterization details were achieved with the application of dentin, enamel, mammelon, incisal, and special effect porcelain powders.

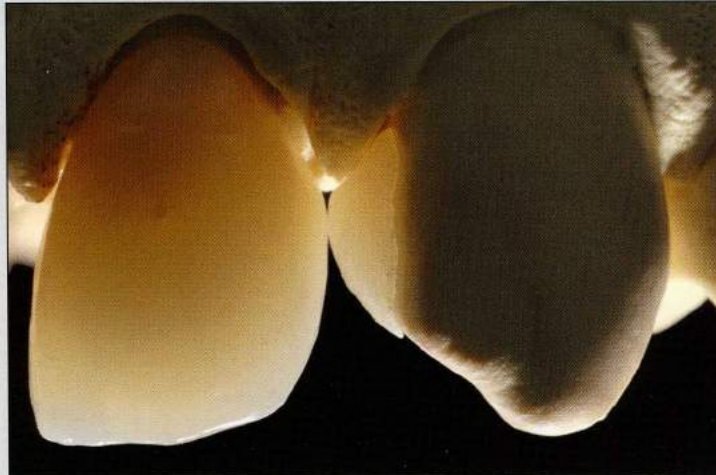
Figs 23a and 23b Proportion Gauge was used in laboratory fabrication and size verification of the restorations. The final tooth size was larger than average, at 9.5 mm in width and 12 mm in length.

Fig 24a Final ceramic restorations are devested and contacts fitted on the solid die cast.



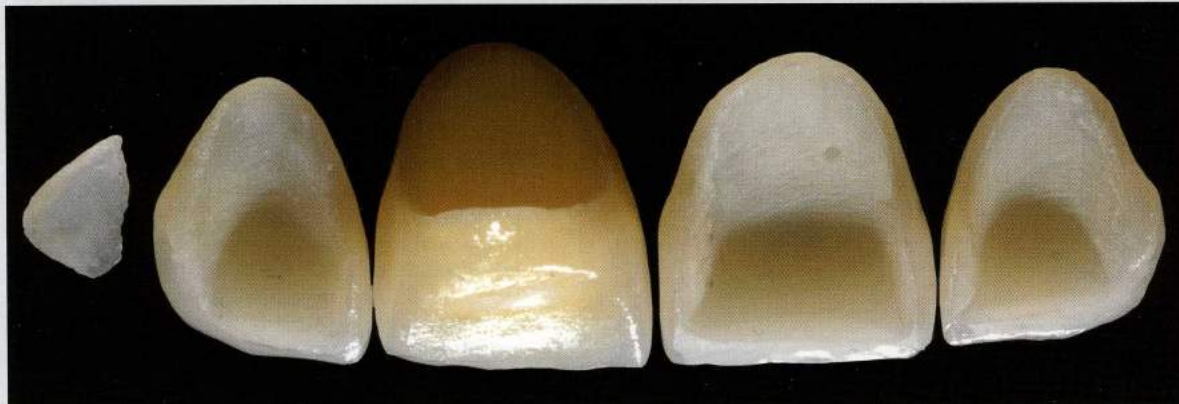24a

Figs 24b and 24c Note the light transmission qualities of the all-ceramic synthetic porcelain material (Venus Porcelain, Heraeus Kulzer, South Bend, IN, USA) for the veneer (left lateral incisor) and no-prep veneer (left canine, mesiofacial). The veneer restorations were prepared in the laboratory for resin cementation/bonding via 90 seconds hydrofluoric acid etching.

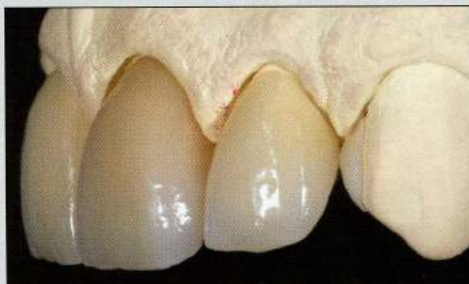

24b

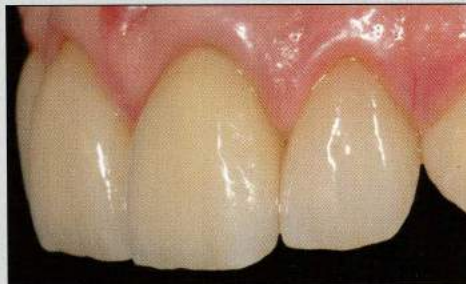Figs 25a and 25b Finished all-ceramic (zirconia-based) restoration (left central incisor) and feldspathic ceramic veneers (right incisors and left lateral and canine) are tried in on the stone cast and clinically following cementation.



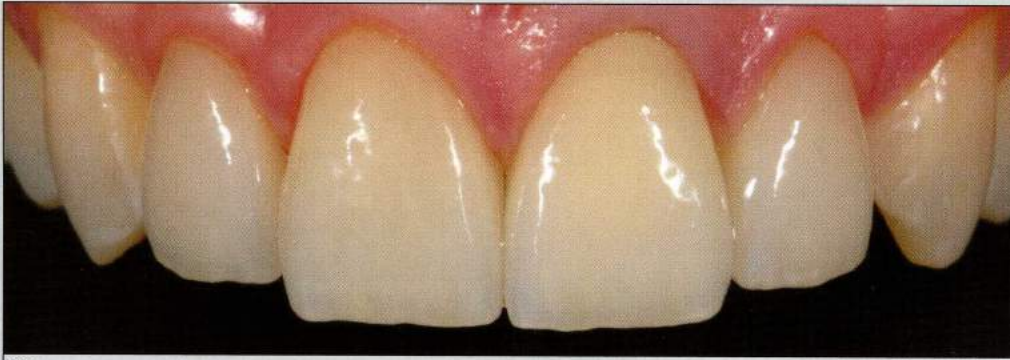24c



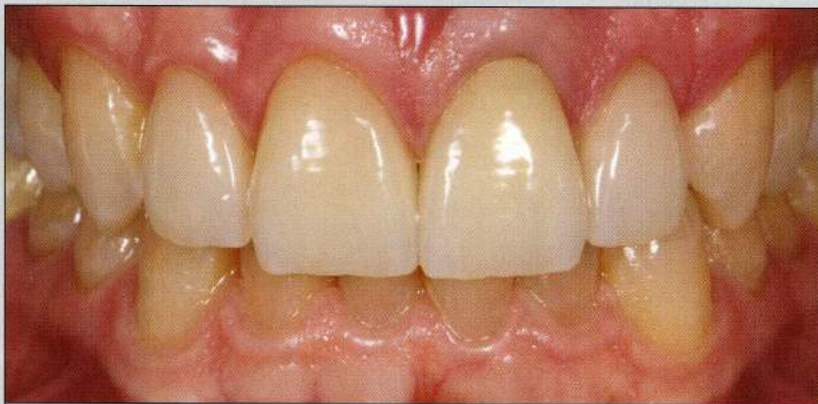25a



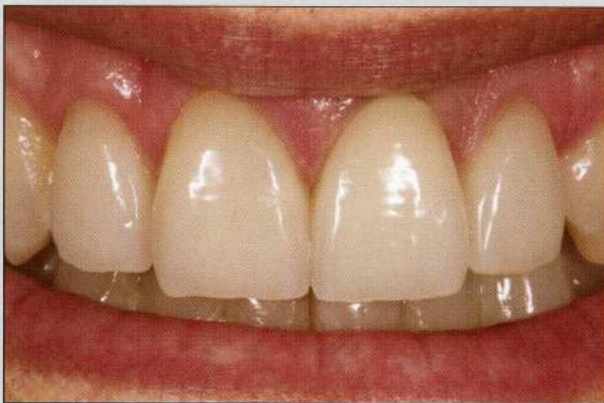25b



26a



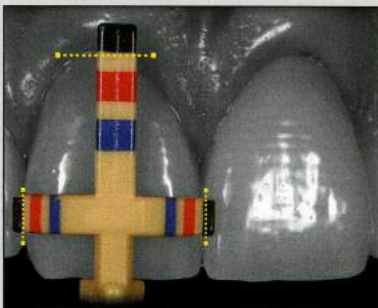
26b



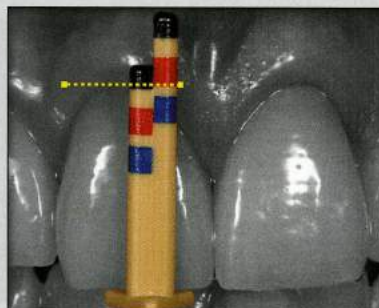
26c

Figs 26a to 26c Try-in also demonstrated that diastemata have been eliminated, and the width and length of the restorations are now in visual harmony within the dental arch.

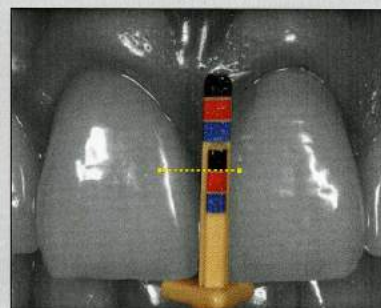
Figs 27a to 27c Final tooth size and proportion of the definitive restorations were verified in the laboratory using the T-Bar tip of the Proportion Gauge. The correct clinical crown length employing esthetic periodontal crown lengthening was created with the aid of the BLPG tip of the Crown Lengthening Gauge and papilla location relative to the corrected tooth length from the incisal edge position.



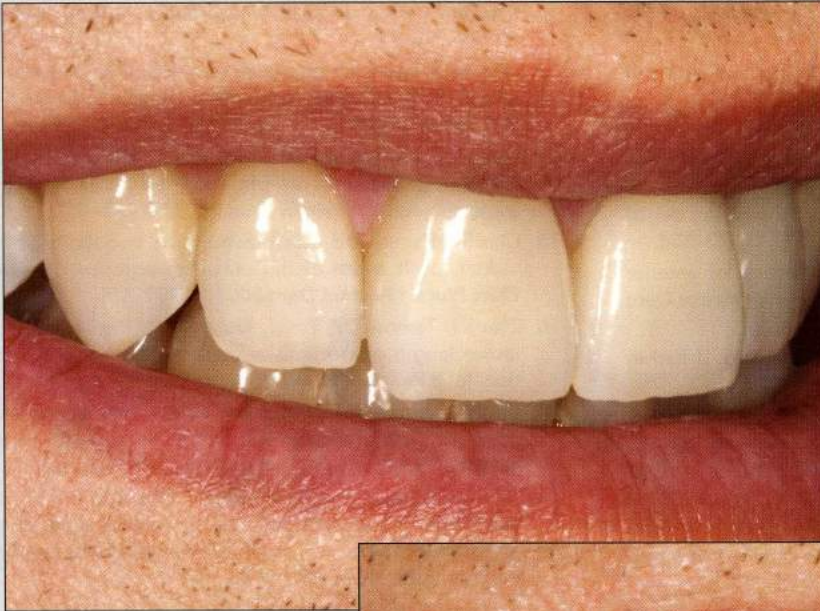27a



27b

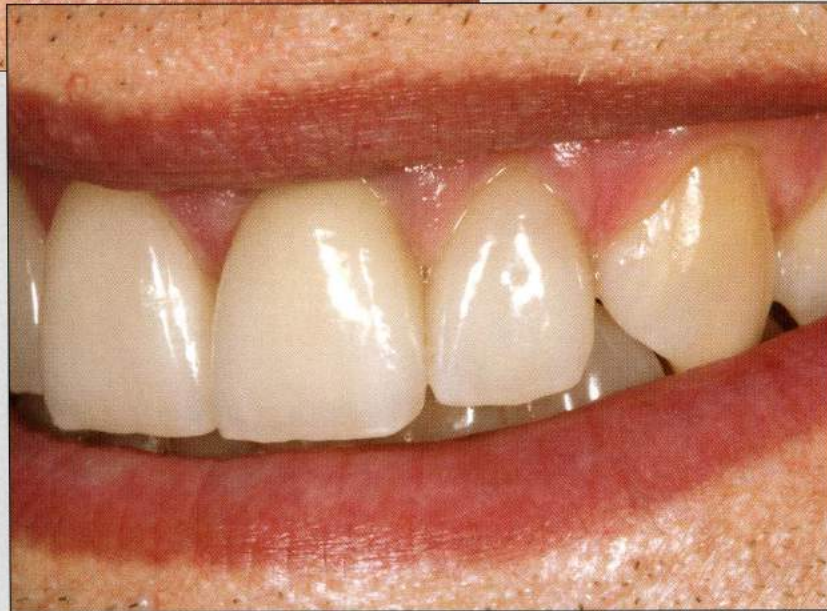

27c



28a

Figs 28a and 28b Extraoral dentofacial views of the esthetic restorative outcome, which demonstrates harmonious correction of tooth proportion and gingival architecture discrepancies commensurate with a pleasing smile.



28b

ACKNOWLEDGMENTS

The author is the inventor of Chu's Aesthetic Gauges and serves as a consultant in the development of esthetic instruments for the Hu-Friedy Co.

REFERENCES

1. Lombardi RE. The principles of visual perception and their clinical application to denture esthetics. *J Prosthet Dent* 1973;29:358-382.
2. Levin EI. Dental esthetics and the golden proportion. *J Prosthet Dent* 1978;40:244-252.
3. Sterrett JD, Oliver T, Robinson F, et al. Width/length ratios of normal clinical crowns of the maxillary anterior dentition in man. *J Clin Periodontol* 1999;26:153-157.

4. Snow SR. Esthetic smile analysis of maxillary anterior tooth width: The golden percentage. *J Esthet Dent* 1999; 11:177-184.
5. Rufenacht CR. *Esthetic Integration*. Chicago: Quintessence, 2000.
6. Rosenstiel SF, Ward DH, Rashid RG. Dentists' preferences of anterior tooth proportion—A web-based study. *J Prosthodont* 2000;9:123-136.
7. Ward DH. Proportional smile design using recurring dental (red) proportion. *Dent Clin North Am* 2001;45:143-154.
8. Rosenstiel SF, Rashid RG. Public preferences for anterior tooth variations: A web-based study. *J Esthet Restor Dent* 2002;14:97-106.
9. Preston JD. The golden proportion revisited. *J Esthet Dent* 1993;5:247-251.
10. Ward DH. A study of dentist's preferred maxillary anterior tooth width proportions: Comparing the recurring esthetic dental proportion to other mathematical and naturally occurring proportions. *J Esthet Restor Dent* 2007;19:324-339.
11. Ward DH. Using the RED proportion to engineer the perfect smile. *Dent Today* 2008;27(5):112,114-117.
12. Gillen RJ, Schwartz RS, Hilton TJ, Evans DB. An analysis of selected normative tooth proportions. *Int J Prosthodont* 1994;7:410-417.
13. Chu SJ. A biometric approach to predictable treatment of clinical crown discrepancies. *Pract Proced Aesthet Dent* 2007;19:401-409.
14. Magne P, Gallucci GO, Belser UC. Anatomic crown width/length ratios of unworn and worn maxillary teeth in white subjects. *J Prosthet Dent* 2003;89:453-461.
15. Chu SJ. Range and mean distribution frequency of individual tooth width of the maxillary anterior dentition. *Pract Proced Aesthet Dent* 2007;19:209-215.
16. Chu SJ, Tarnow DP, Tan J, Stappert C. Papilla height to crown length proportions in the maxillary anterior dentition. *Int J Periodontics Restorative Dent* 2009 (in press).
17. Chu SJ, Hochman M, Fletcher P. A biometric approach to aesthetic crown lengthening: Part II—Interdental considerations. *Pract Proced Aesthet Dent* 2008 (in press).
18. Tarnow DP, Wagner AW, Fletcher P. The effect of the distance from the contact point to the crest of bone on the presence or absence of the interproximal dental papilla. *J Periodontol* 1992;63:995-996.