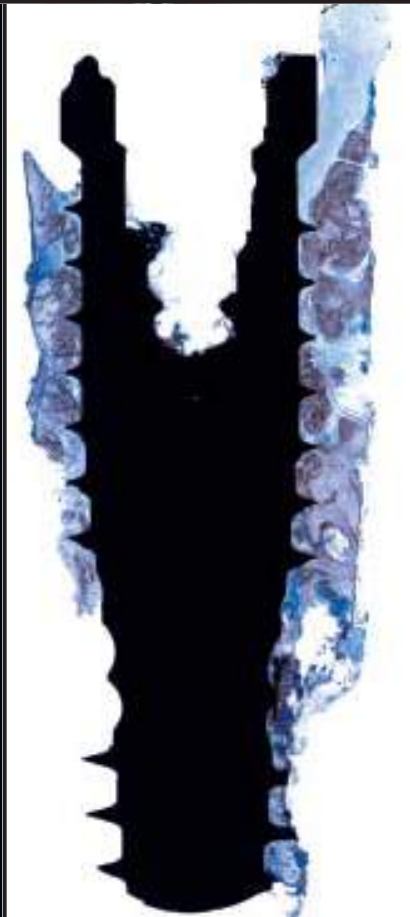
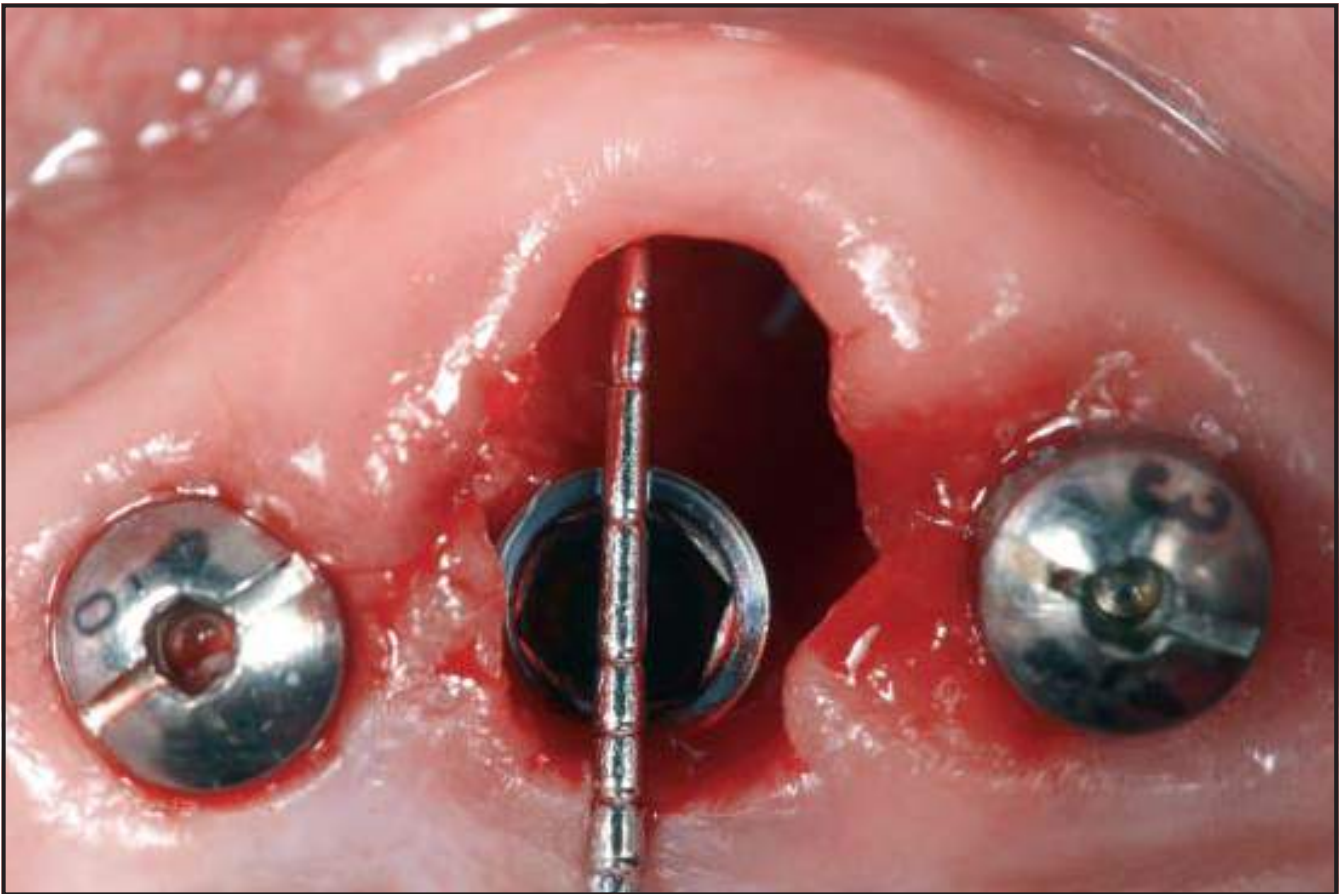
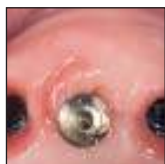Human Histologic Verification of Osseointegration of an Immediate Implant Placed into a Fresh Extraction Socket With Excessive Gap Distance Without Primary Flap Closure, Graft, or Membrane: A Case Report



Dennis P. Tarnow, DDS*
Stephen J. Chu, DMD, MSD, CDT**

The aim of this research was to verify clinically and histologically whether an excessively large horizontal and vertical gap distance of an implant placed into an immediate extraction socket would osseointegrate coronally at the implant-socket interface without primary flap closure, a bone graft, or a barrier membrane. An immediate implant and straight-profile healing abutment were placed at the palatal aspect of the extraction socket replacing a nonrestorable maxillary left canine. The residual horizontal defect measured 4.2 mm buccolingually and was allowed to heal by secondary intention. The implant was loaded after 5 months and biopsied after 10 months of placement, using the coronal portion of the buccal bone. The histologic section of the coronal aspect of the implant interface revealed intimate bone contact to the first thread. There was reestablishment of the implant biologic width coronal to the bone contact with connective tissue and junctional epithelium. This case report provides clinical and histologic proof that the immediate placement of implants into extraction sockets with an intact buccal wall allows healing and osseointegration despite a large gap distance and without primary flap closure, a bone graft, or a barrier membrane. (Int J Periodontics Restorative Dent 2011;31:515-521.)

*Clinical Professor and Director of Implant Education, Columbia University College of Dental Medicine, New York, New York.

**Clinical Associate Professor and Director of Esthetic Education, Columbia University College of Dental Medicine, New York, New York.

Correspondence to: Dr Dennis P. Tarnow, Specialized Dentistry of New York, 150 E. 58th Street, Suite 3200, New York, NY 10155; fax: 212-754-6753; email: dennistarnow@gmail.com.

The immediate placement of implants into extraction wounds is performed to decrease the healing time for patient treatment.¹⁻³ Some advocate primary closure,⁴ while others allow healing to occur via secondary intention.^{5,6} The dilemma facing implants placed in fresh extraction sockets has been the horizontal distance between the implant surface and the labial plate of bone. Clinical healing appears to be noneventful in most cases, but the question remains as to the interface of implant and bone.⁷⁻¹⁰

It has been postulated that a connective tissue interface will develop when the gap is greater than 1.5 mm at the coronal aspect of the implant. Some suggest the distance should be 0.5 mm or less.⁷⁻¹⁰ There is no available information on the implant-labial bone interface with secondary wound healing. It is apparent that the single common feature of previous studies is the effort to accomplish primary flap closure over the gap without a membrane.⁷⁻¹² The cascade of events of extraction wound

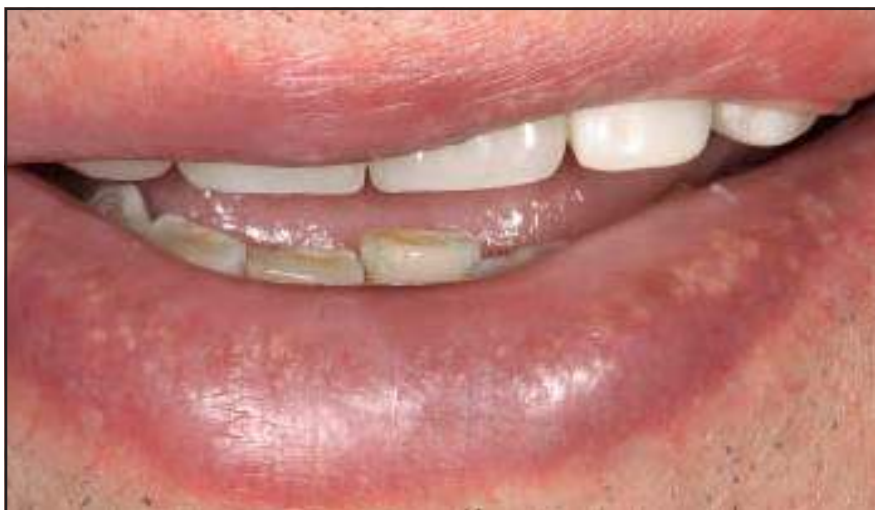

Fig 1 Patient at maximum smiling showing a low midfacial and interdental smile line.

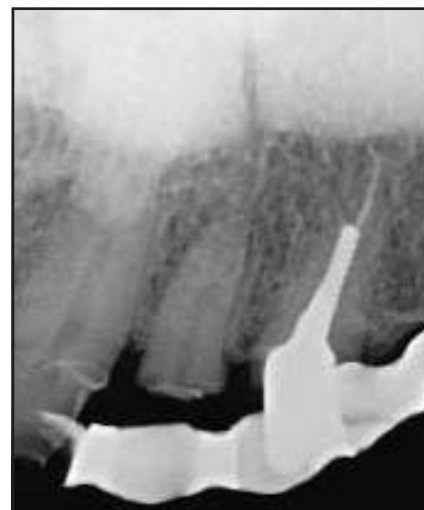

Fig 2 Maxillary lateral-canine radiograph showing the subgingival residual root at the left lateral incisor and very large case foundation restoration at the canine with little to no ferrule effect and recurrent caries. Restoration of the lateral incisor would require endodontic treatment, and both teeth would need crown lengthening surgery prior to definitive restoration if saved.

healing without implants reveals a time frame of some weeks before re-epithelialization. The explanation for the delay is that the avascular epithelium at the socket periphery depends on the underlying connective tissue for vascular nourishment: The blood supply is forthcoming from the alveolar bone lining the extraction wound, and immediate postextraction blood clots do not contain new vasculature for some days until angiogenesis occurs.¹³

The question, then, is when an implant is placed into an extraction socket and heals by secondary intention without flap closure, what is the sequence of events that occur? This is reminiscent of the epithelial race with soft tissues from

the periphery of the wound. It is necessary to test this hypothesis with a clinical case supported by a histologic assay. If the hypothesis is true, the horizontal distance of the gap would not be significant because the granulation tissue from the socket wall would result in bone development at the implant surface rather than connective tissue from the marginal border of the socket.

Therefore, the purpose of this clinical report was to provide histologic validation to the hypothesis that a gap distance greater than 1.5 mm between the implant surface and the buccal plate of bone would result in bone-to-implant contact when healing by secondary intention.

Case report

A 75-year-old Caucasian man presented for treatment of his maxillary dentition that included an existing metal-reinforced provisional fixed partial denture with tooth abutments at the central incisors, left canine, and left second molar. He selected a fixed partial denture treatment plan. The patient demonstrated a clenching habit and had a very low smile line (Fig 1).¹⁴

Clinical and radiographic examination revealed that the left lateral incisor had a fracture extending to the free gingival margin and the left canine was restored with a post and core restoration after experiencing recurrent caries (Fig 2).¹⁵ The root

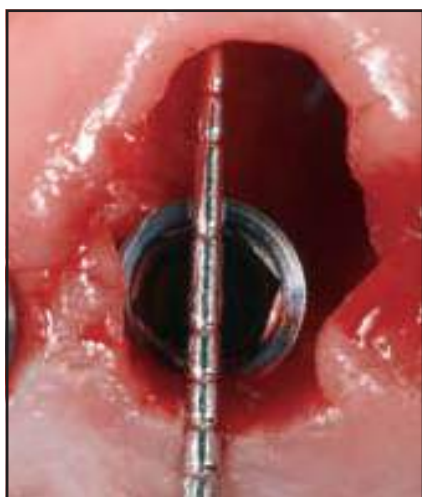

Fig 3 A threaded internal connection implant (NanoTite NT) was placed at the palatal aspect of the extraction socket. A residual gap distance of approximately 4.2 mm buccolingually was measured with a periodontal probe.

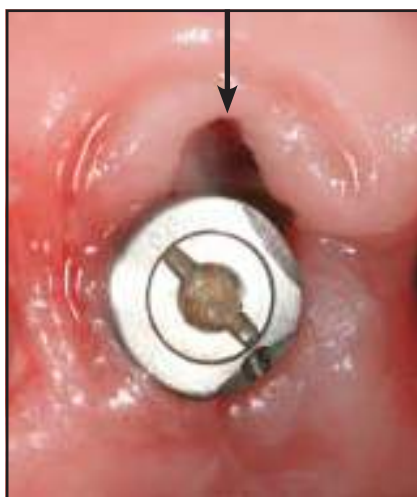

Fig 4 A fibrin clot (arrow) was visible in the socket 1 week postextraction.

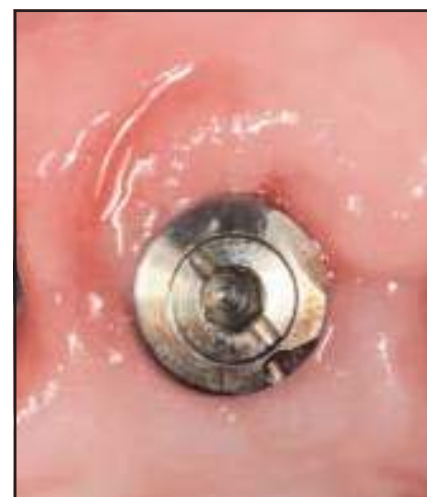

Fig 5 After 9 weeks, the young tissue appeared keratinized.

of the left canine was tapered with inadequate coronal tooth structure that would compromise long-term retention and restoration.¹⁶ A transitional extraction treatment plan was performed that retained the tooth to help support the provisional restoration. Implants were placed at the left lateral incisor, first and second premolars, and first molar sites as the first phase of treatment. After integration and loading, the canine was extracted sans flap elevation, and a NanoTite tapered implant (13 × 4 mm; Biomet 3i) was placed. There was a horizontal gap of 4.2 mm separating the implant from the inner surface of the buccal plate (Fig 3). The defect healed without primary closure, a bone graft, or a barrier

membrane. A healing abutment was placed, and a provisional fixed partial denture covered the surgical site.

The free facial gingival margin collapsed slightly over the socket after 1 week of healing, and a fibrin clot was visible within the socket (Fig 4). The gingival tissue appeared to be keratinized and completely surrounded the abutment after 9 weeks (Fig 5).

Restorative impressions were made 8 months after the implants were placed. Single-unit metal-ceramic restorations were made for implants at the left lateral incisor, canine, and second molar sites as well as for both central incisors (natural abutment teeth) (Fig 6). A three-unit fixed partial denture was

fabricated to reach from the left first premolar to first molar sites.

The patient agreed to biopsy removal of the implant at the left canine, with informed consent based on the Helsinki Declaration of 1975, as revised in 2000. The biopsy took place 10 months after placement and 5 months after occlusal loading. The purpose of the biopsy was to verify that the gap between the implant and buccal plate of bone had filled with bone and excellent bone-to-implant contact had been achieved via secondary intention wound healing.

A cone beam computed tomography scan of the implant at the left canine demonstrated 3.12 mm of bone at its buccal aspect

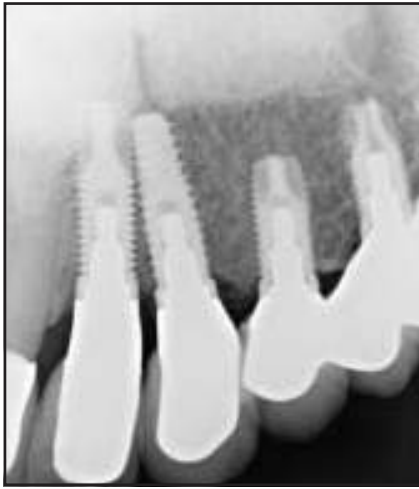


Fig 6 (left) Radiograph of the healed and restored immediate implant placed at the left canine site.

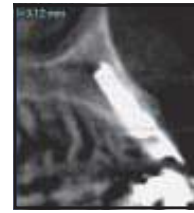

Fig 7 (right) Cone beam computed tomography scan of the implant at the left canine site 5 months after restoration and 10 months after placement. A measurement of 3.12 mm of radiographic buccal bone was noted.

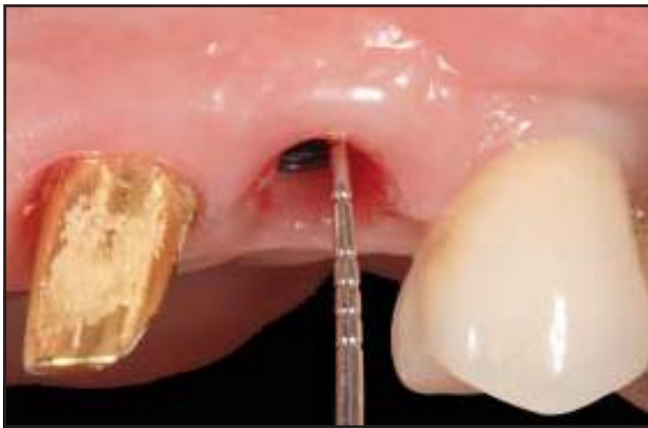

Fig 8 (above) Sounding of the hard tissue was performed with a periodontal probe; 3 mm was recorded on the direct facial aspect of the implant.

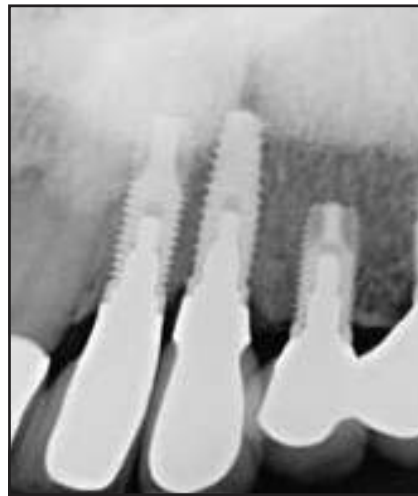

Fig 9 (right) Radiograph of the replaced implant restoration of the left canine 6 months post-implant replacement and 11 months after implant removal.

(Fig 7). This implant was placed for potential functional support, but the success of the other implants made it superfluous. Bone sounding of the osseous crest was performed using a periodontal probe, and a distance of 3 mm from the free gingival margin was recorded on the direct facial aspect of the

implant (Fig 8). Histologic evidence was necessary to ultimately substantiate intimate bone-to-implant contact.

The implant and a section of the buccal plate were biopsied under local anesthesia. The site was regenerated with bone allograft (Puros, Zimmer) and covered with

an absorbable collagen membrane (BioMend Extend, Zimmer). The patient received 2 g of amoxicillin 1 hour preoperative and 500 mg every 6 hours for the following week. A replacement implant was placed 5 months after grafting, and a new single-tooth restoration was constructed (Fig 9).

Histologic processing

The specimen was placed in 10% formalin and sent for histologic processing (Fig 10a). It was embedded, sectioned, ground, polished, and stained for light microscopy examination. The implant and surrounding tissue were subject to graded ethanol substitution, defatted with acetone, infiltrated with Technovit 7200 resin (EXAKT Technologies), and cured in the EXAKT 520 Light Polymerization Unit. The polymerized block was mounted to an EXAKT stain-free plastic histology slide, sectioned using the EXAKT 300 CP Band System, and ground to 110 μm using the EXAKT 400 CS Grinding System. The section was then polished using a Buehler Ecomet III to a 1- μm surface finish and a section thickness of approximately $100 \pm 4 \mu\text{m}$.

The section was stained using toluidine blue and imaged on a Leica DM5000 B microscope (Leica Microsystems) using a Leica HC PL Fluotar 20/0.50 objective lens. Images were acquired with a Leica DFC290 color video camera and QWin (V3.40) image acquisition system (Leica Microsystems). Image field widths were equal to 475 μm .

Syncroscopy Montage Explorer software (Synoptics) was employed to create the high-resolution macro-image using a Leica-Leitz DMRX/E Universal Microscope (Leica Microsystems) configured with a Marzhauser motorized stage, a Leica PL Fluotar 5/0.12 objective lens, and a JVC KYF55B color video camera. The scale was represented by the implant screw pitch of 811 μm .

Histologic findings

The junctional epithelium extended 0.5 mm from the coronal aspect of the implant (Fig 10b) to the connective tissue attachment (Fig 10c), which ended at the first thread of the implant (Fig 10d). The bone-to-implant contact began at this point, evidencing osseointegration with normal healing for this implant design.

Discussion

Wound healing with variable gap distances between the buccal plate and implant surface continues to be somewhat controversial. A horizontal gap distance greater than 1.5 mm was shown to heal with connective tissue on the implant surface when primary flap closure was used. It is possible that the connective tissue from the flap with primary closure migrates to the implant surface before bone develops. This histologic specimen presents evidence that it is possible for bone to reach the surface first when allowing the socket to heal by secondary intention, as occurs routinely with dental extractions. The soft tissues from the marginal gingiva appear not to migrate over the clot until the granulation tissue in the socket matures. It is possible then that an implant placed in an extraction site without soft tissue closure could heal with bone-to-implant contact before the soft tissues have an opportunity to interfere.

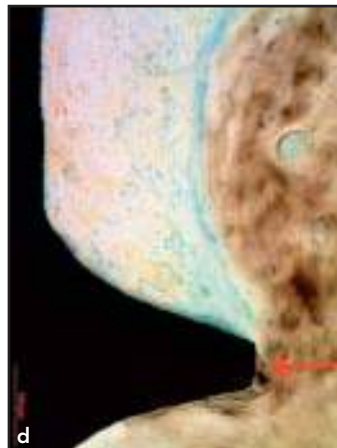
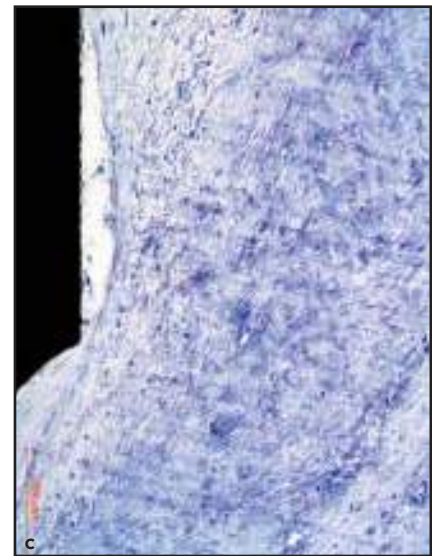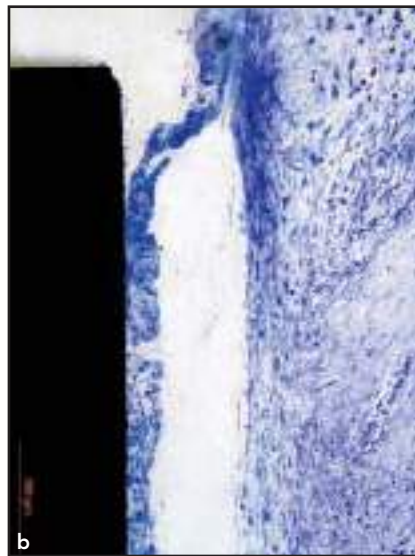



Fig 10a Histologic processing revealed evidence that osseointegration (bone-to-implant contact at the implant-socket interface) was present at the first thread without any graft material, membrane, or primary flap closure. The 4.2-mm gap was left to repair undisturbed by secondary intention wound healing.

Fig 10b The most coronal aspect of the junctional epithelial attachment approximately 0.5 to 1.0 mm from the abutment-implant connection. The epithelium was separated during sounding of the implant interface in Fig 10a (magnified view of highlighted area A).

Fig 10c Connective tissue zone apical to the junctional epithelium shown in Fig 10b (magnified view of highlighted area B).

Fig 10d Note the arrow showing the most coronal point of bone-to-implant contact at the first thread. This shows that bone was able to grow across the gap before the connective tissue from the flap could do so. The fact that no primary closure or flap was performed is critical to this occurring (magnified view of highlighted area C).

The effect of the thickness of the buccal plate at the time of implant placement is not understood completely and may be related to the fact that approximately 90% of labial plates in the maxillary anterior region were 1 mm or less in thickness.^{17,18} The original probing on this extracted canine found the

buccal plate to be 4.2 mm from the implant. The computed tomography scan after healing found the labial plate of bone to be 3.2-mm wide, indicating some remodeling of the buccal plate as the gap to the implant surface filled with bone. It is unknown whether a thick buccal plate is required or if a thin buccal

plate might be sufficient, although some studies demonstrate significant loss of buccal plate when no grafting is performed. The thickness could be problematic when a flap is elevated, which would compromise the blood supply from the periosteum.

The implant was placed at the level of the buccal crest, allowing the restoration to have a flat emergence profile from the sulcus. The vertical defect was not measured because there was no thought of biopsy when it was placed. Questions have risen regarding the possibility of bacterial contamination when the soft tissues are not coapted. It appears that clot formation in the first few minutes functions as a cover and binds to the surface of the implant. Therefore, the clot is mechanically attached to the implant threads and microtexture of the implant surface. This might prevent contamination unless the clot is dislodged.

Conclusions

This case report provides proof-of-principle clinical and histologic evidence that the immediate placement of implants into extraction sockets with a thick intact buccal plate can result in osseointegration with bone-to-implant contact to the first thread in the presence of a 4.2-mm gap. The socket was allowed to heal by secondary intention without flap closure, a bone graft, or a barrier membrane. The effects of adding bone grafting material in the gap were not explored in this case report. Continued research is required on this type of wound healing to evaluate predictability.

References

1. Barzilay I, Graser GN, Caton J, Shenkle G. Immediate implantation of pure titanium threaded implants into extraction sockets. *J Dent Res* 1988;67:234.
2. Barzilay I, Graser G, Iranpour B, Natiella JR. Immediate implantation of a pure titanium implant into an extraction socket: Report of a pilot procedure. *Int J Oral Maxillofac Implants* 1991;6:277–284.
3. Lazarra RJ. Immediate implant placement into extraction sites: Surgical and restorative advantages. *Int J Periodontics Restorative Dent* 1989;9:332–343.
4. Warrer L, Gotfredsen K, Hjørting-Hansen E, Karring T. Guided tissue regeneration ensures osseointegration of dental implants placed into extraction sockets. An experimental study in monkeys. *Clin Oral Implants Res* 1991;2:166–171.
5. Kan JY, Rungcharassaeng K, Lozada JL. Immediate placement and provisionalization of maxillary anterior single implants: 1-year prospective study. *Int J Oral Maxillofac Implants* 2003;18:31–39.
6. Chen ST, Darby IB, Reynolds BC. A prospective clinical study of non-submerged immediate implants: Clinical outcomes and esthetic results. *Clin Oral Implants Res* 2007;18:552–562.
7. Carlsson L, Rostlund T, Albrektsson B, Albrektsson T. Implant fixation improved by close fit. Cylindrical implant-bone interface studied in rabbits. *Acta Orthop Scand* 1988;59:272–275.
8. Knox R, Caudill R, Meffert R. Histologic evaluation of dental endosseous implants placed into surgically created extraction defects. *Int J Periodontics Restorative Dent* 1991;11:365–375.
9. Botticelli D, Berglundh T, Buser D, Lindhe J. The jumping distance revisited: An experimental study in the dog. *Clin Oral Implants Res* 2003;14:35–42.
10. Botticelli D, Berglundh T, Buser D, Lindhe J. Appositional bone formation in marginal defects at implants. *Clin Oral Implants Res* 2003;14:1–9.
11. Akimoto K, Becker W, Persson R, Baker DA, Rohrer MD, O'Neal RB. Evaluation of titanium implants placed into simulated extraction sockets: A study in dogs. *Int J Oral Maxillofac Implants* 1999;14:351–360.
12. Wilson TG Jr, Schenk R, Buser D, Cochran D. Implants placed in immediate extraction sites: A report of histologic and histometric analyses of human biopsies. *Int J Oral Maxillofac Implants* 1998;13:333–341.
13. Amler MH, Johnson PL, Salman I. Histological and histochemical investigation of human alveolar socket healing in undisturbed extraction wounds. *J Am Dent Assoc* 1960;61:32–44.
14. Tjan AH, Miller GD, The JG. Some esthetic factors in a smile. *J Prosthet Dent* 1984;51:24–28.
15. Libman WJ, Nicholls JI. Load fatigue of teeth restored with cast posts and cores and complete crowns. *Int J Prosthodont* 1995;8:155–161.
16. Goto Y, Nichols JI, Phillips KM, Junge T. Fatigue resistance of endodontically treated teeth restored with three dowel-and-core systems. *J Prosthet Dent* 2005;93:45–50.
17. Huynh-Ba G, Pjetursson BE, Sanz M, et al. Analysis of the socket bone wall dimensions in the upper maxilla in relation to immediate implant placement. *Clin Oral Implants Res* 2010;21:37–42.
18. Sanz M, Cecchinato D, Ferrus J, Pjetursson EB, Lang NP, Lindhe J. A prospective, randomized-controlled clinical trial to evaluate bone preservation using implants with different geometry placed into extraction sockets in the maxilla. *Clin Oral Implants Res* 2010;21:13–21.